



NINGBO 1st HOSPITAL

Vulnerable plaque and thrombosis inside DES

**Heart center , Ningbo First Hospital
Honghua Ye**

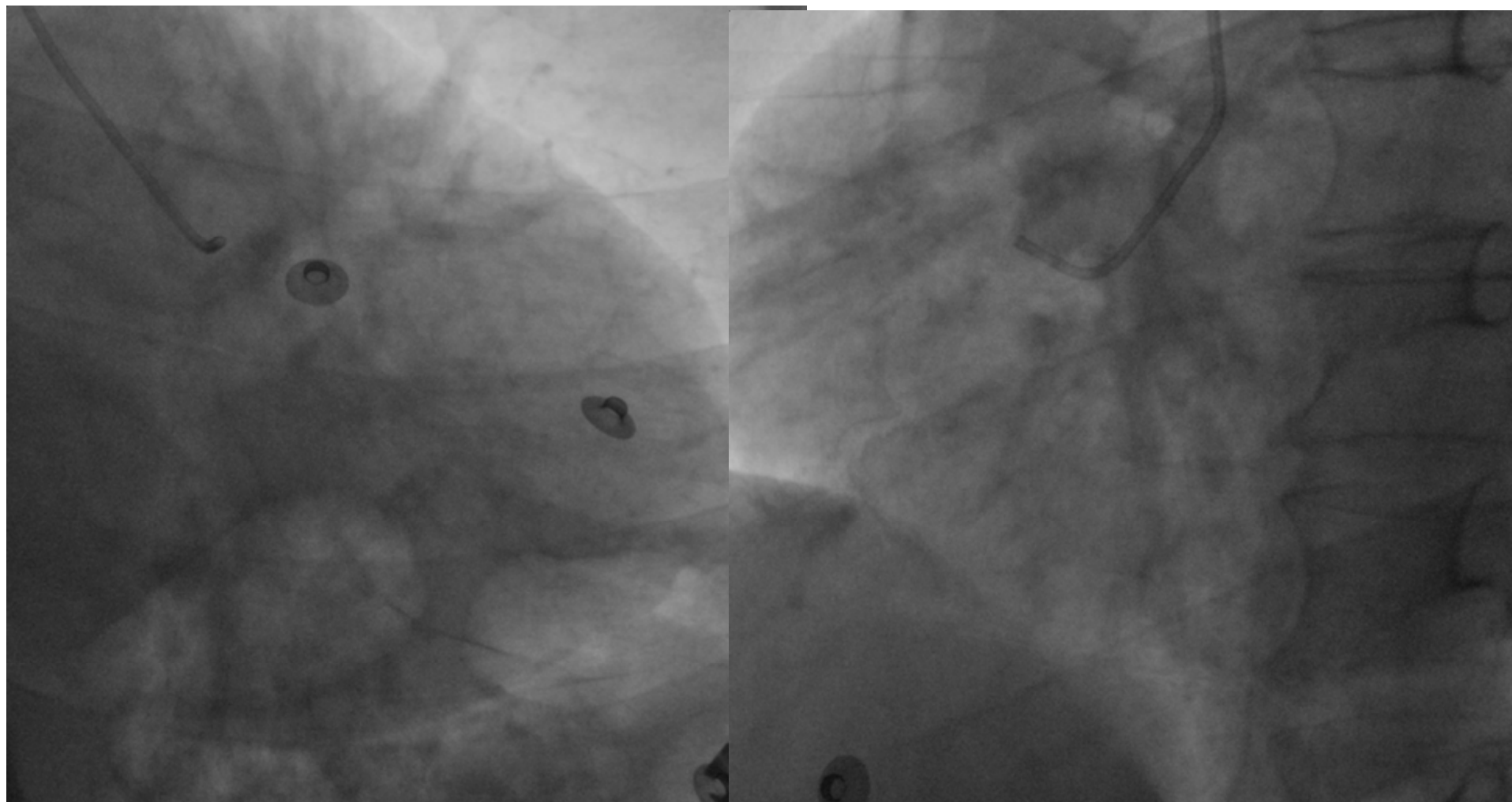

- 75 year old male
- Hypertension for 12 years, smoking for 30 years (quitted smoking 10 years ago)
- Jan, 2007: Cypher 3.0×33 was implanted in LAD and Endeavor 3.0×33 was implanted in LCX for unstable angina.
- Nov, 2011: admitted again for ACS.

2007-1-9

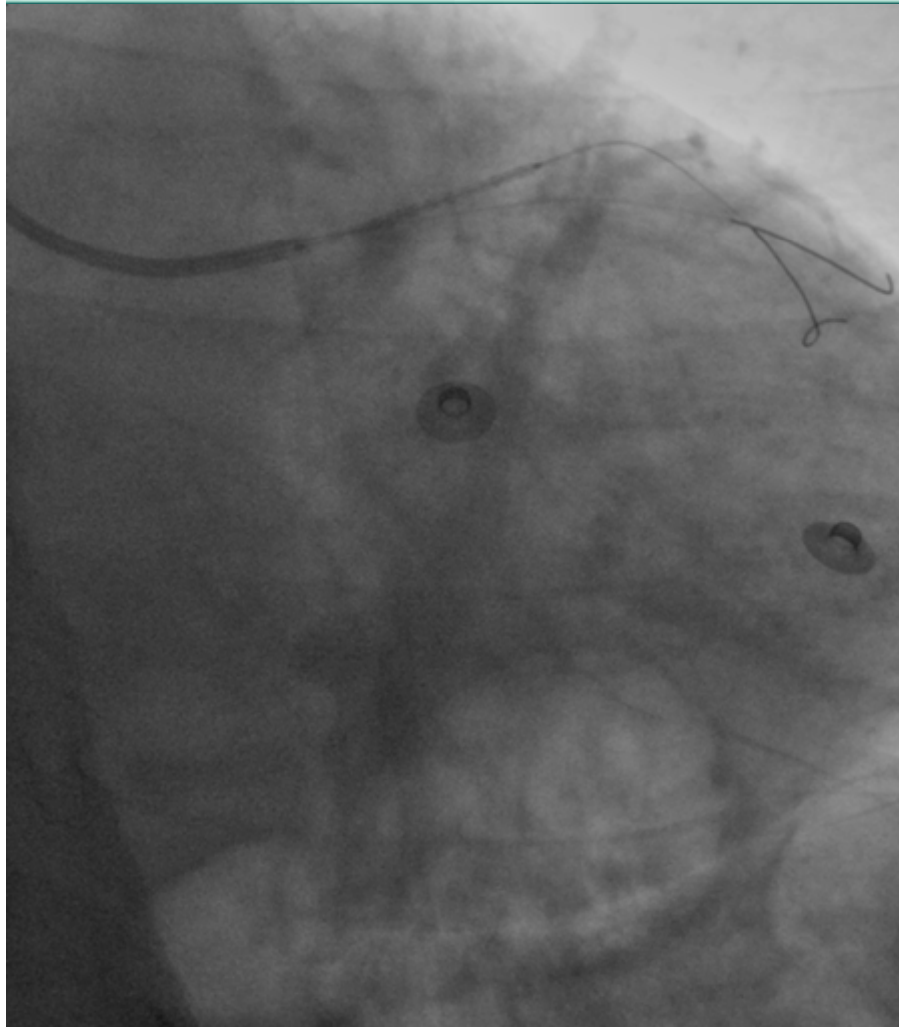
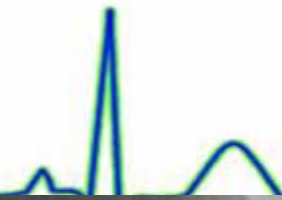


NINGBO 1st HOSPITAL

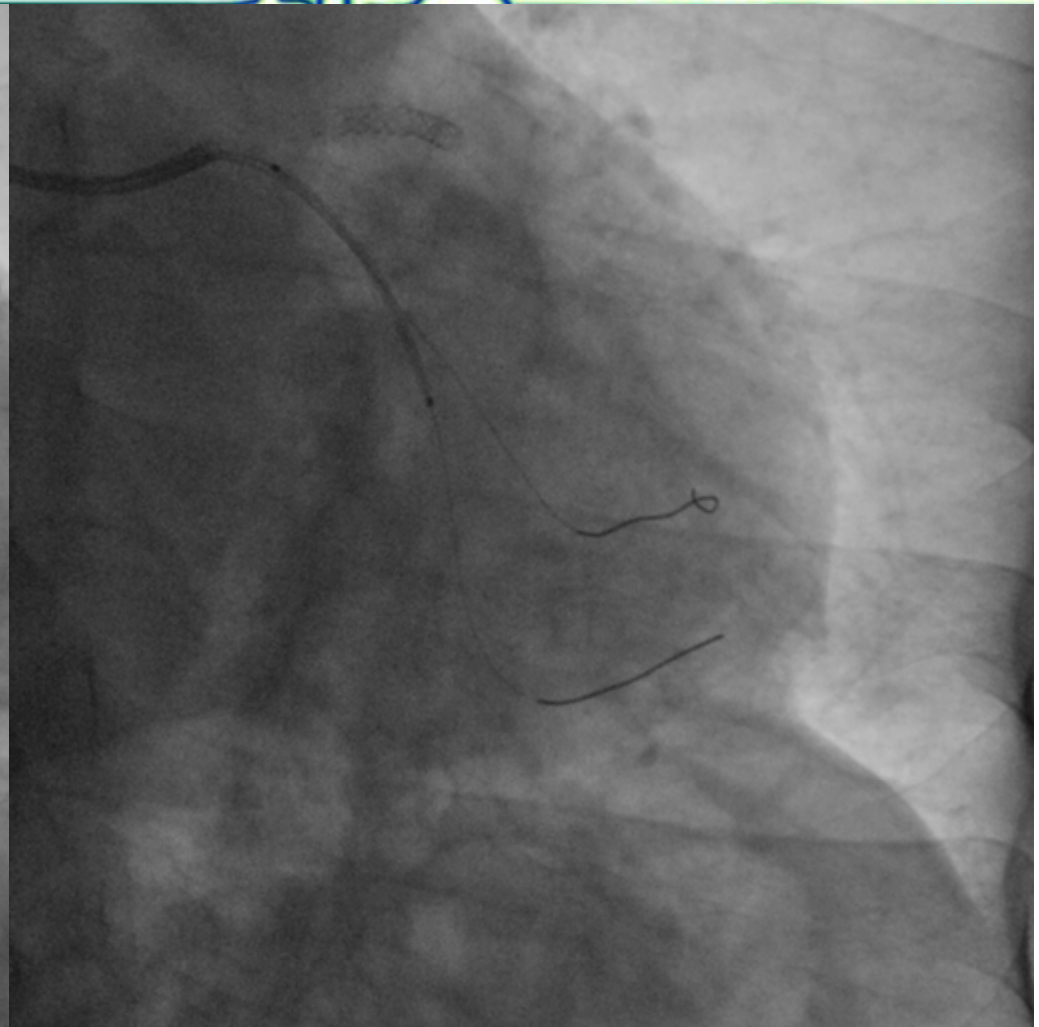



NINGBO 1st HOSPITAL



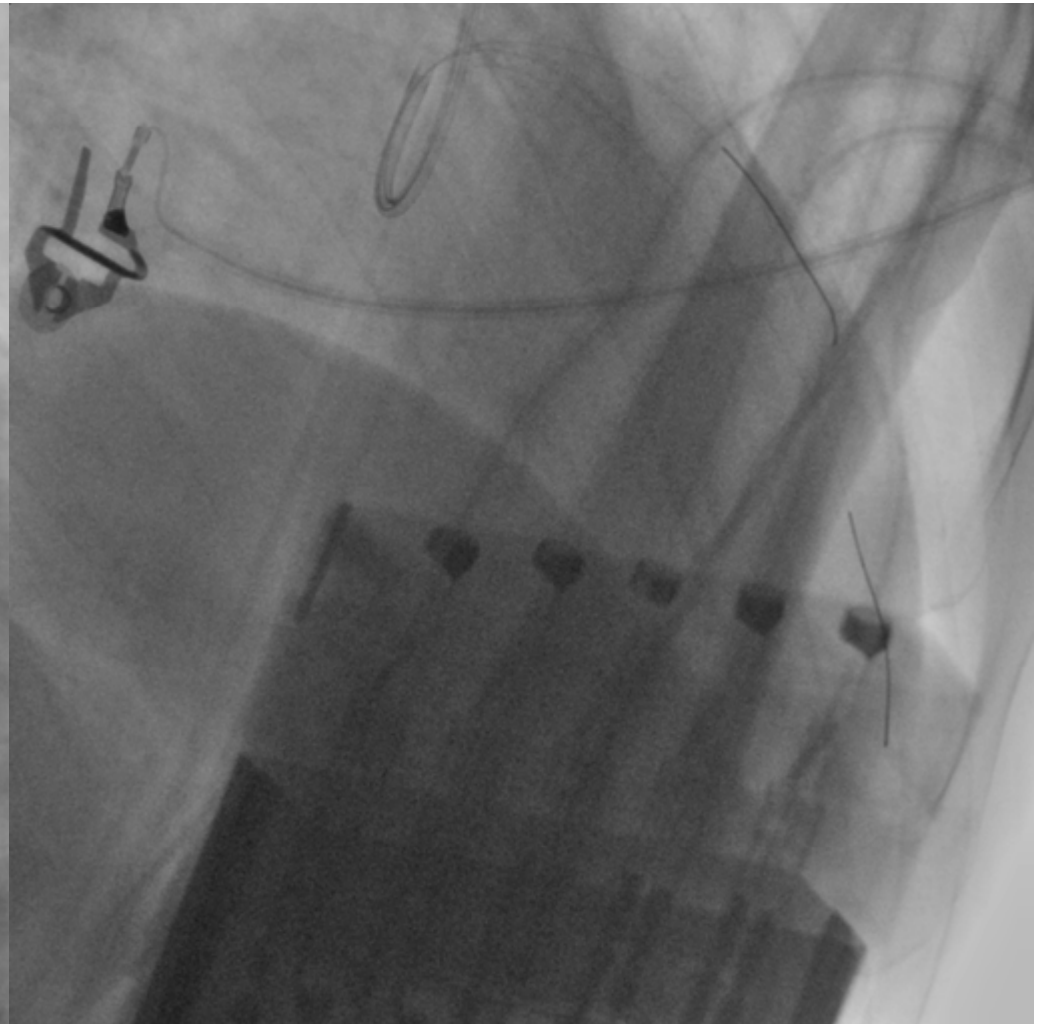
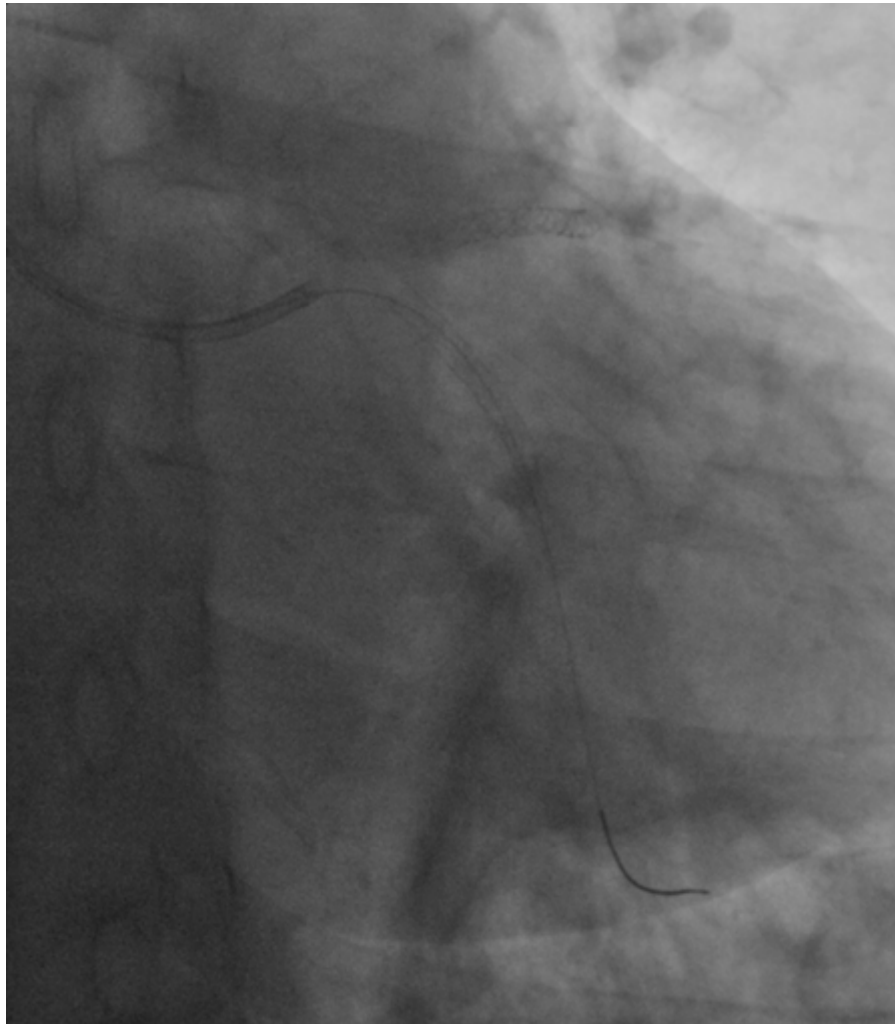Cypher 3.0*33mm

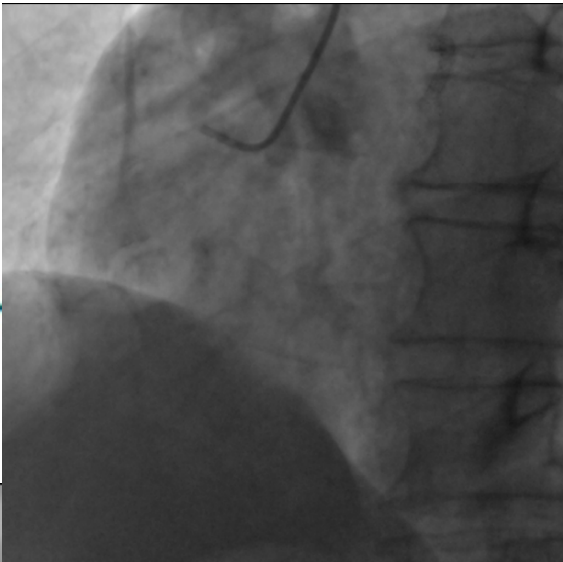


Endeavor 3.0*30mm

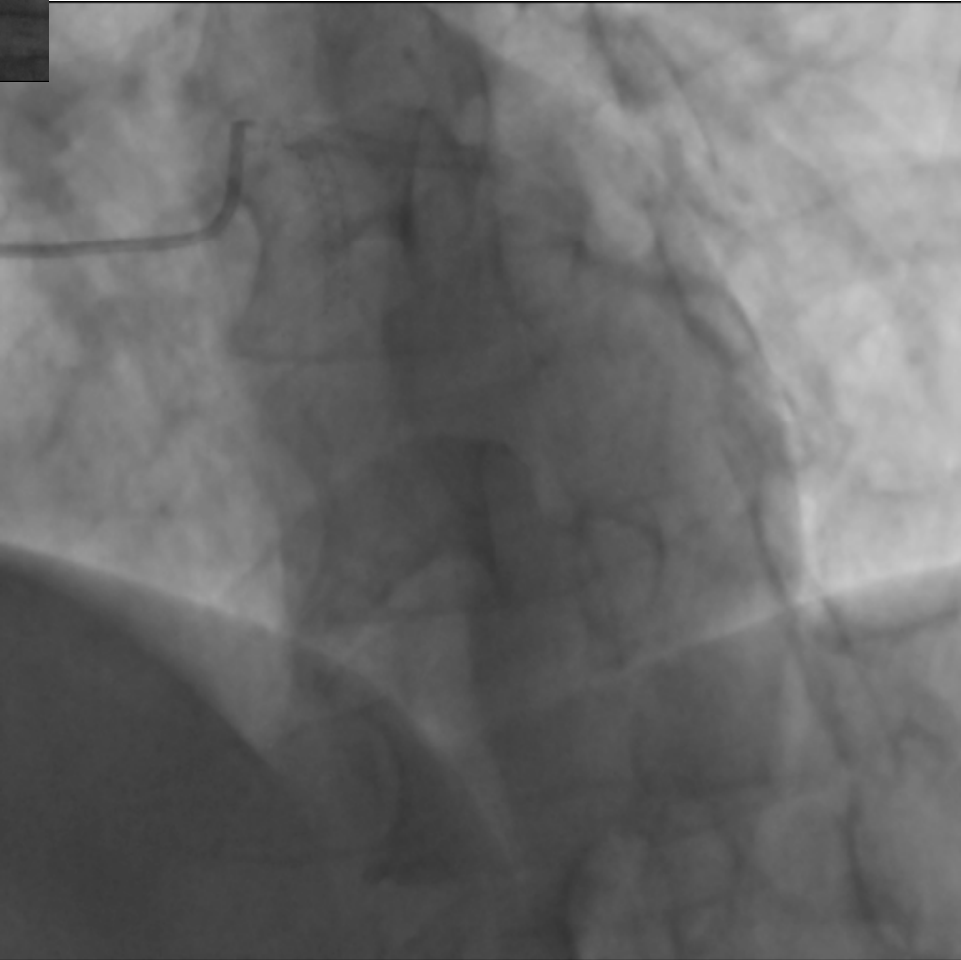
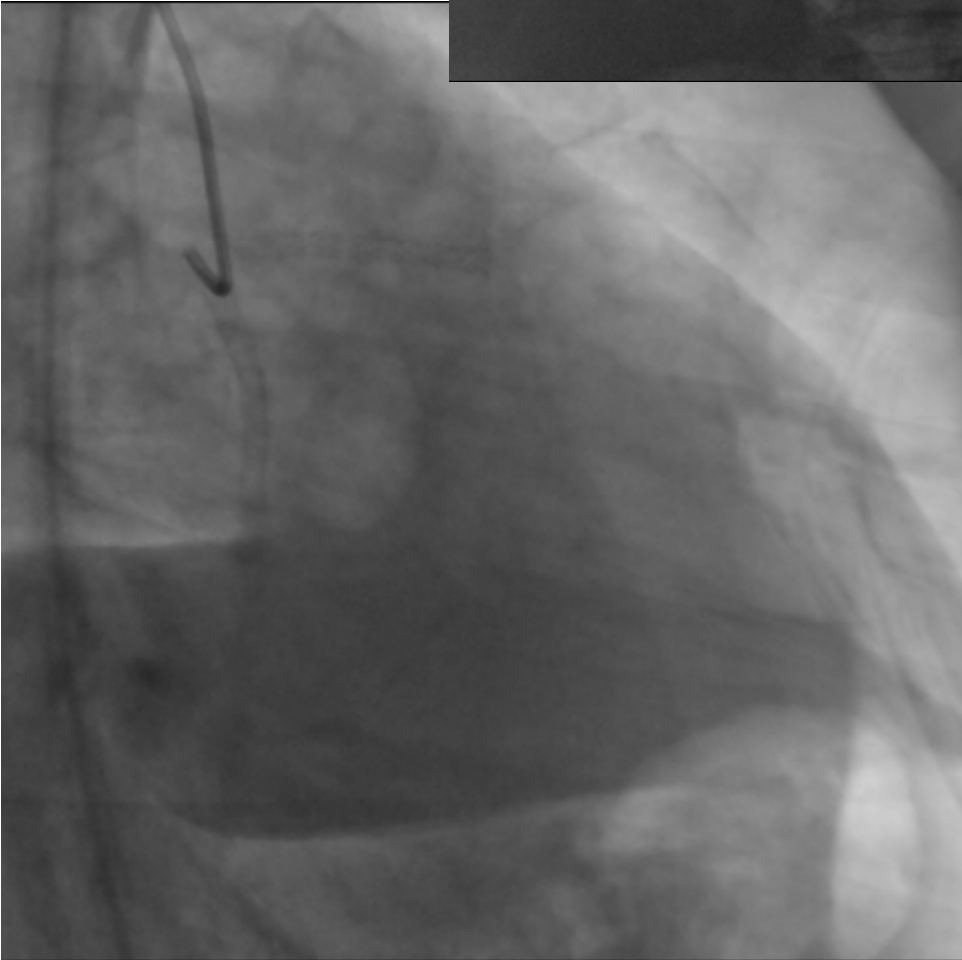


NINGBO 1st HOSPITAL



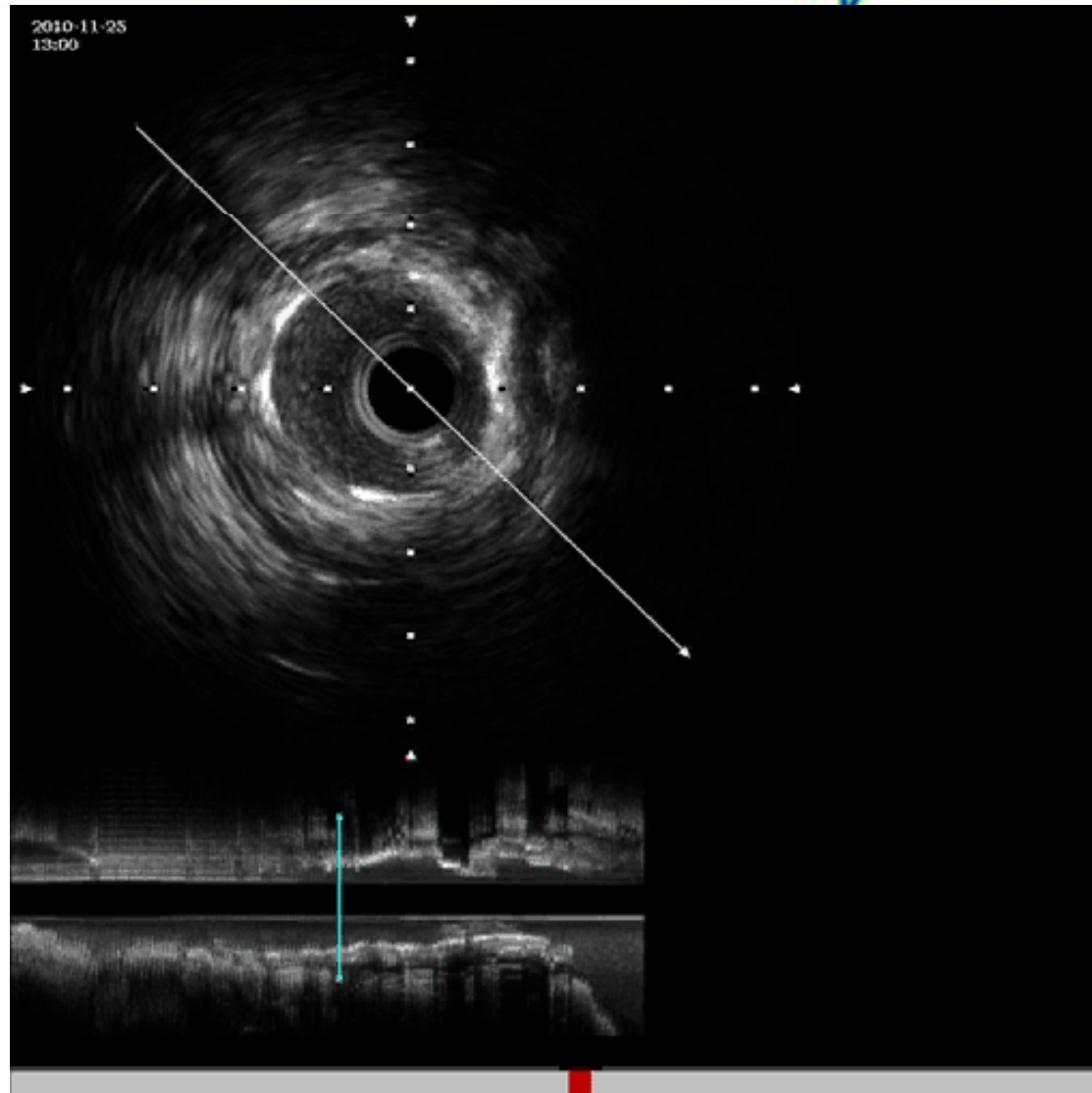


2010-11-25



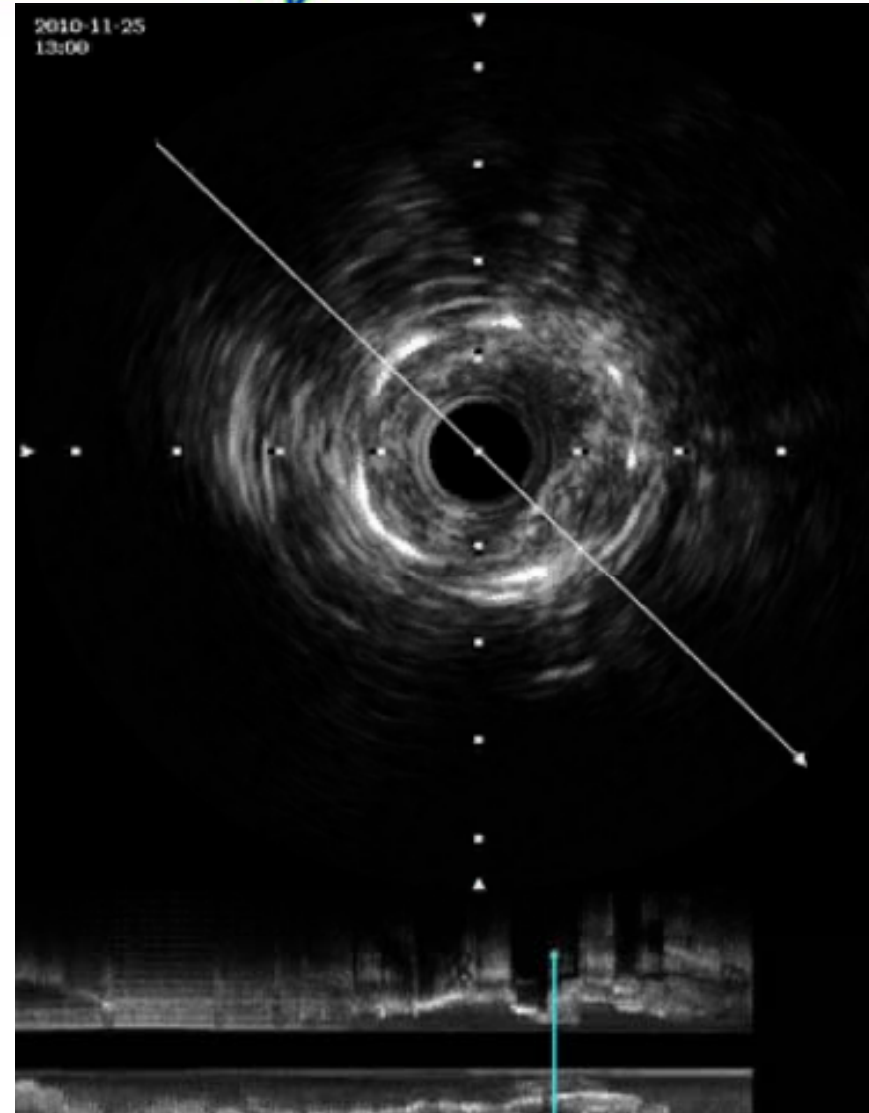
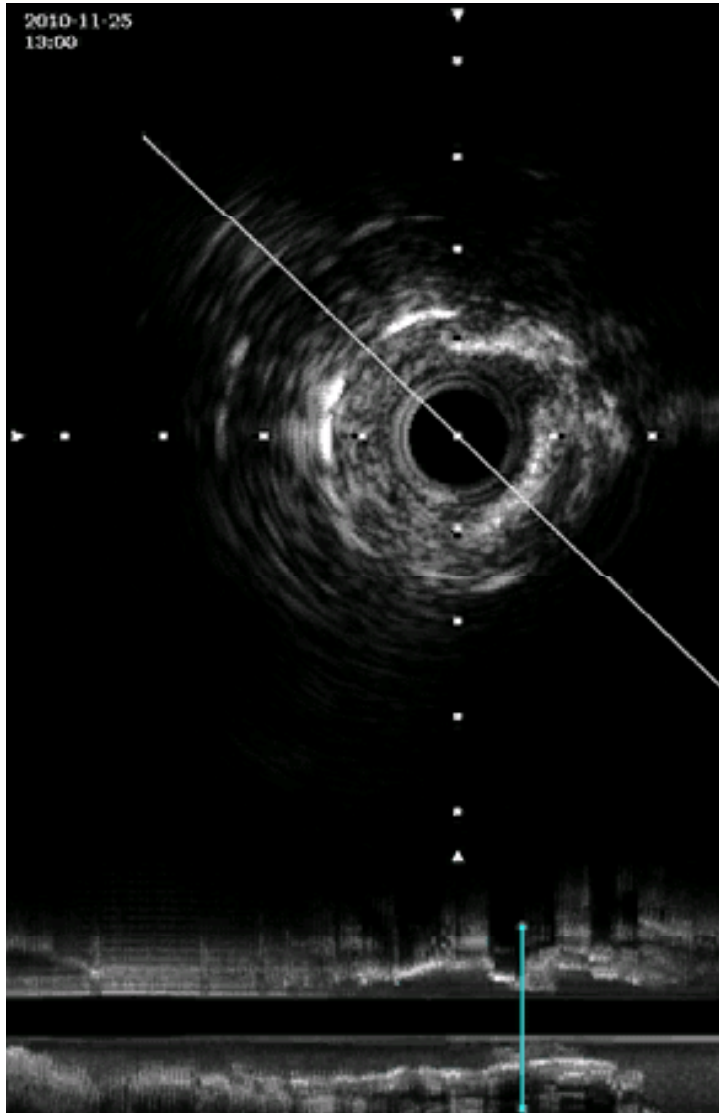


NINGBO 1st HOSPITAL



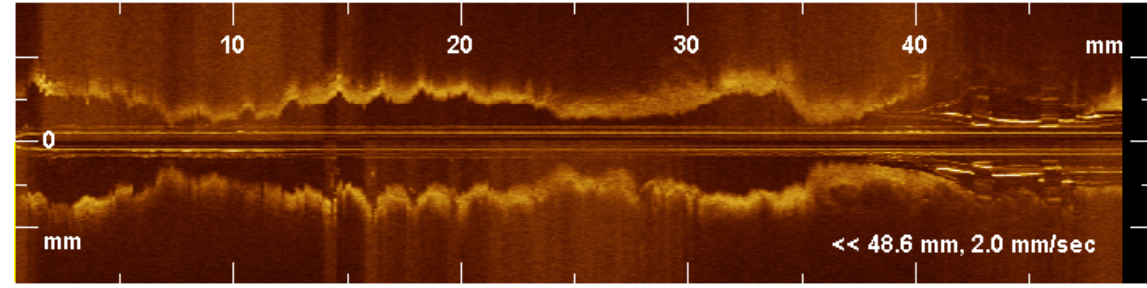
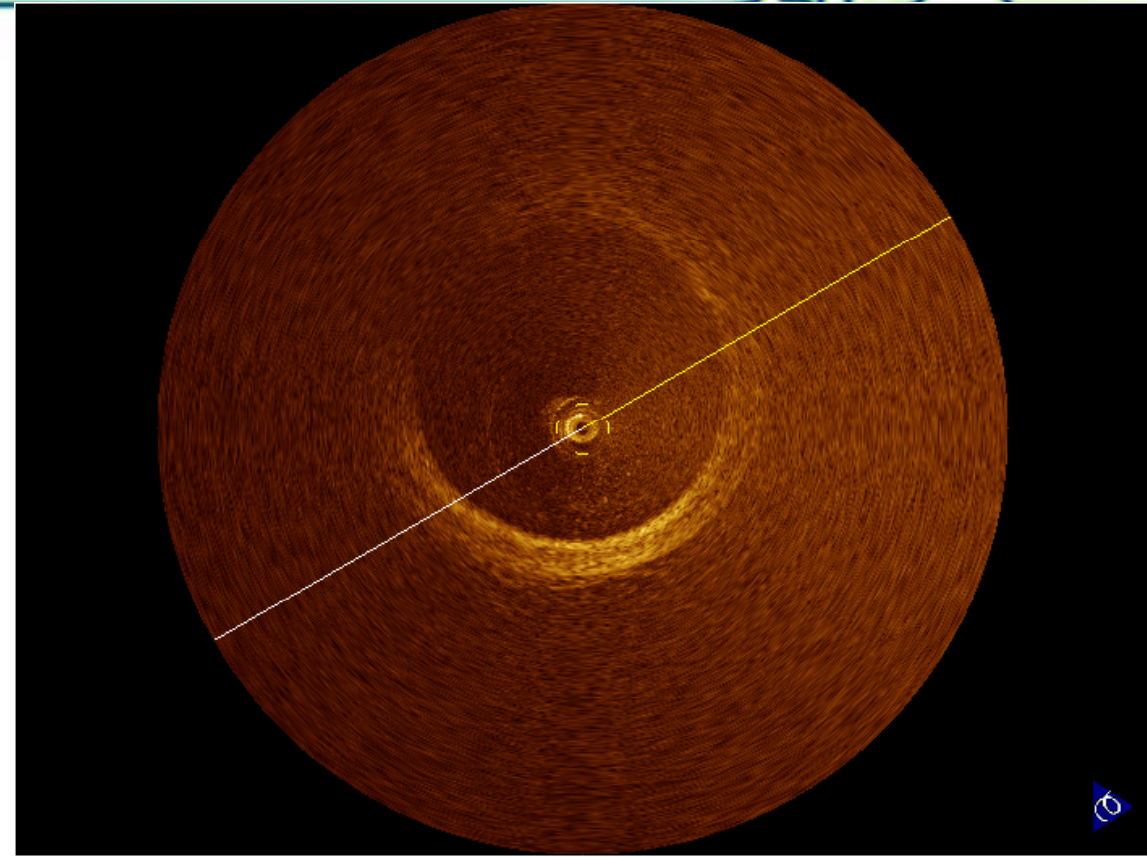


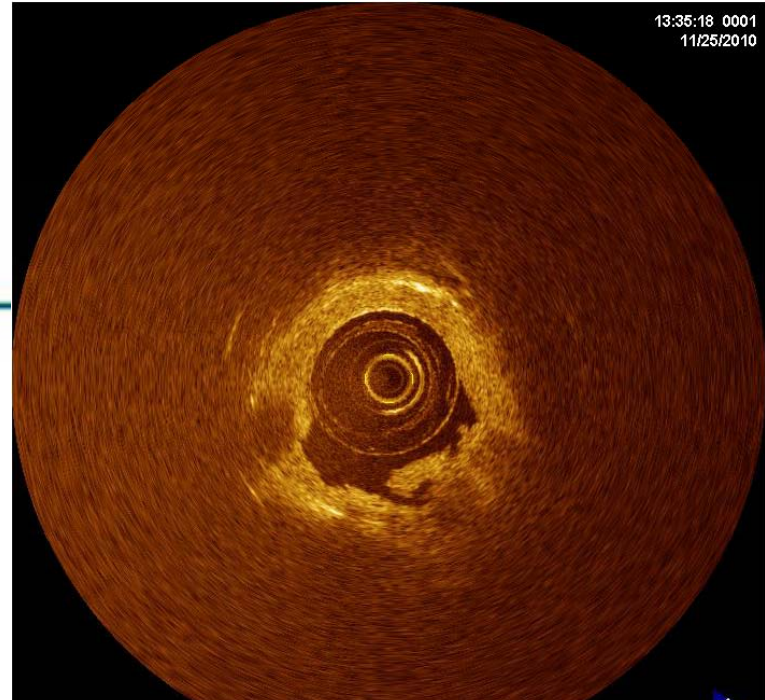
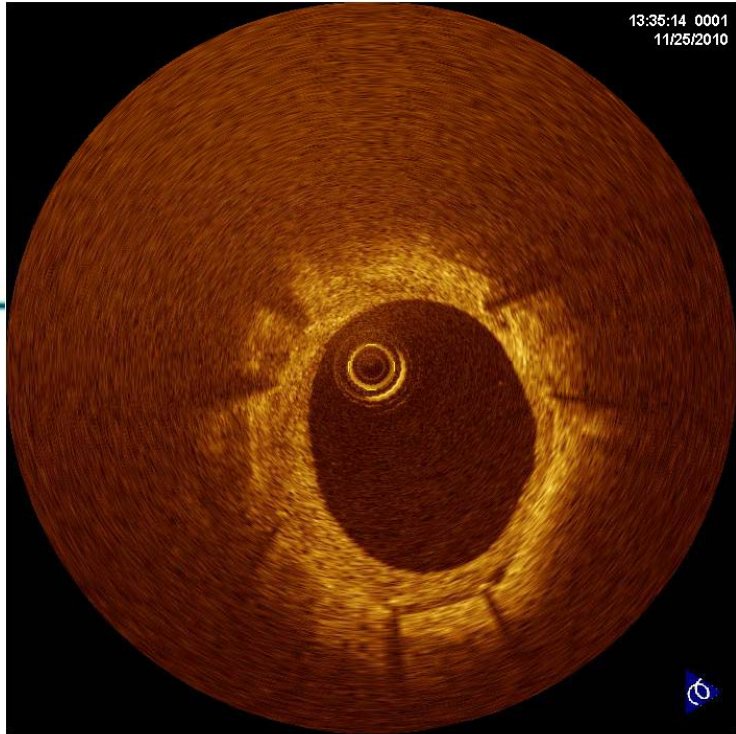
NINGBO 1st HOSPITAL



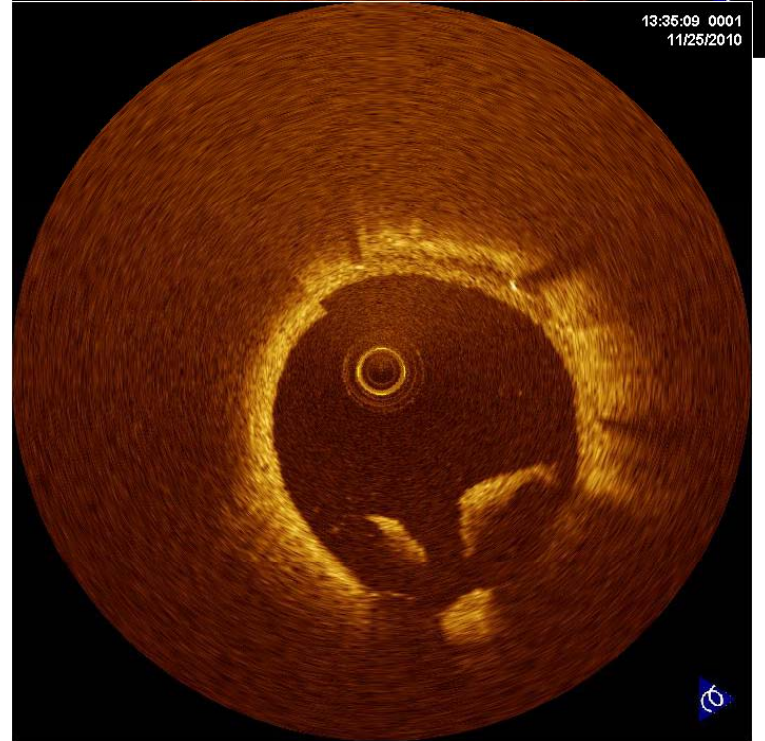
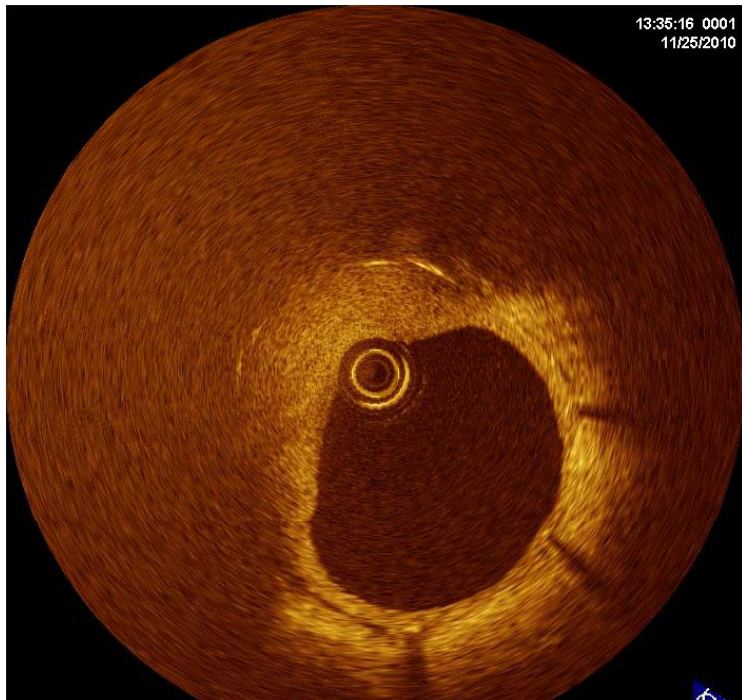


NINGBO 1st HOSPITAL



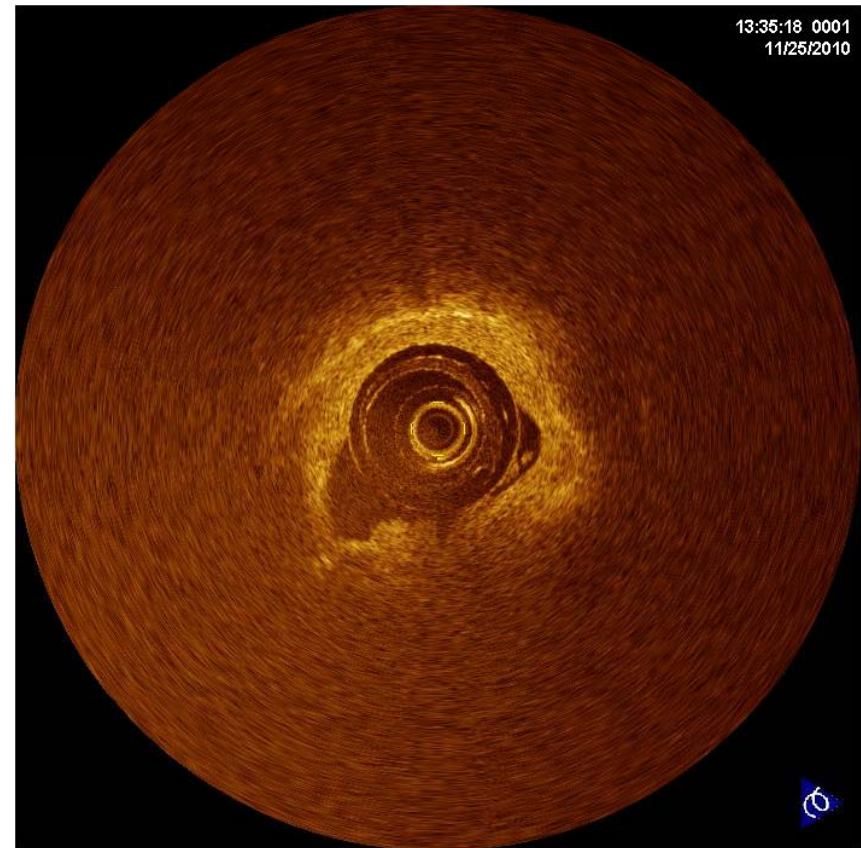
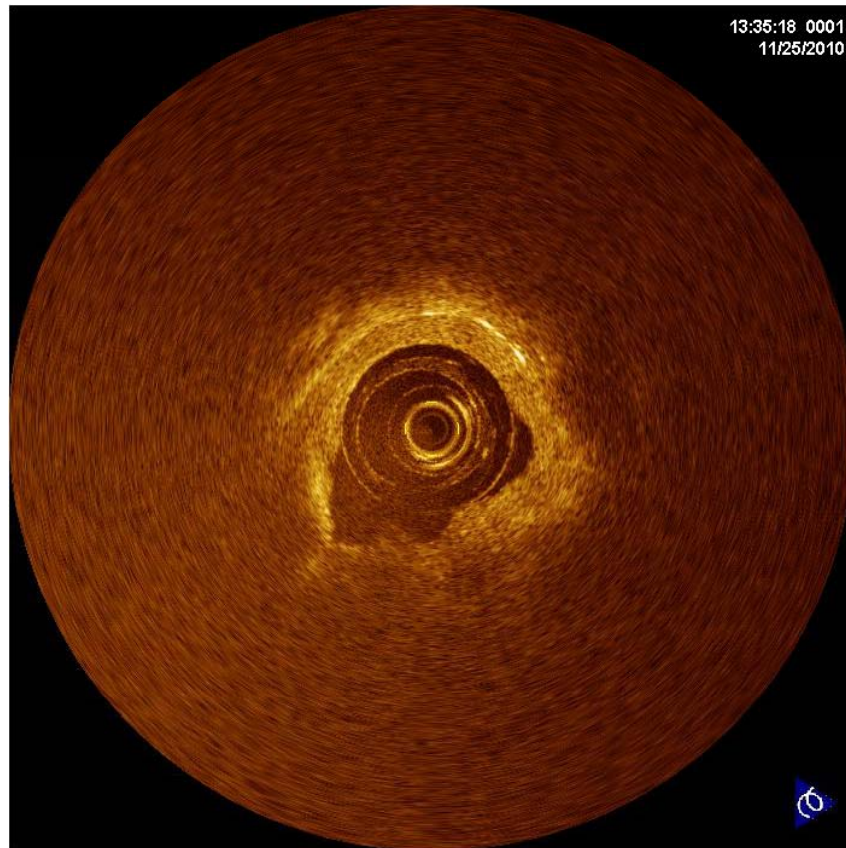


ITAL



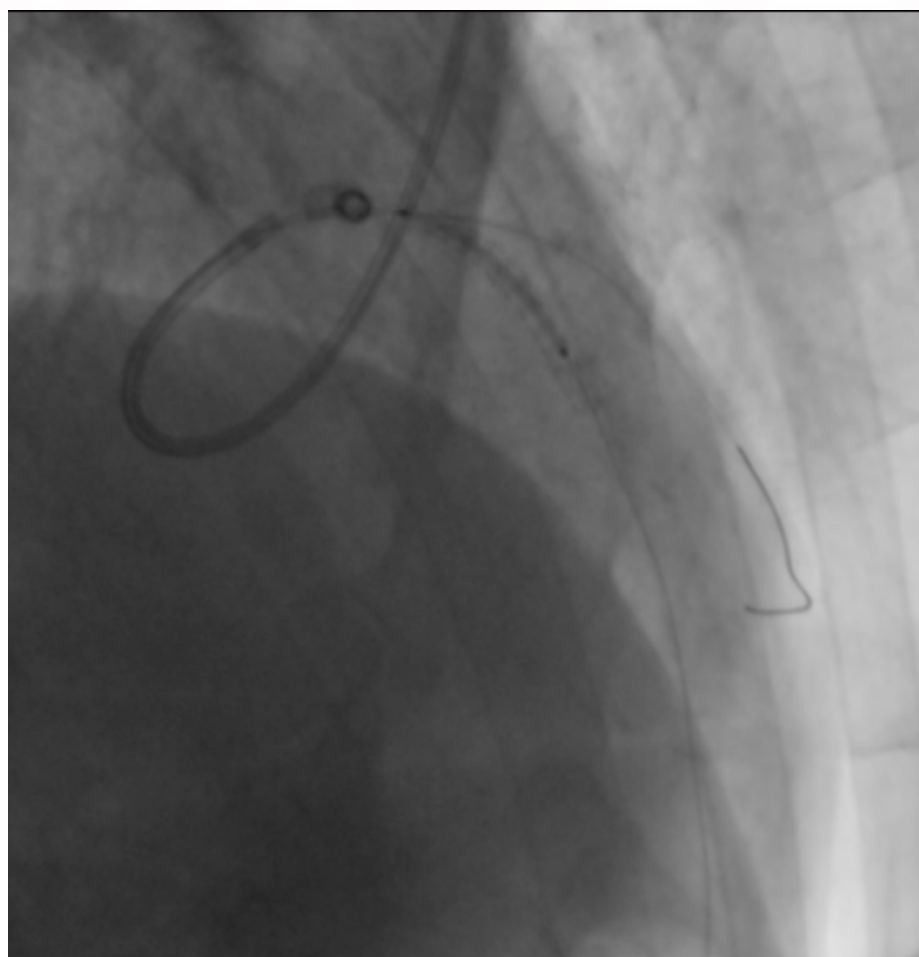


NINGBO 1st HOSPITAL

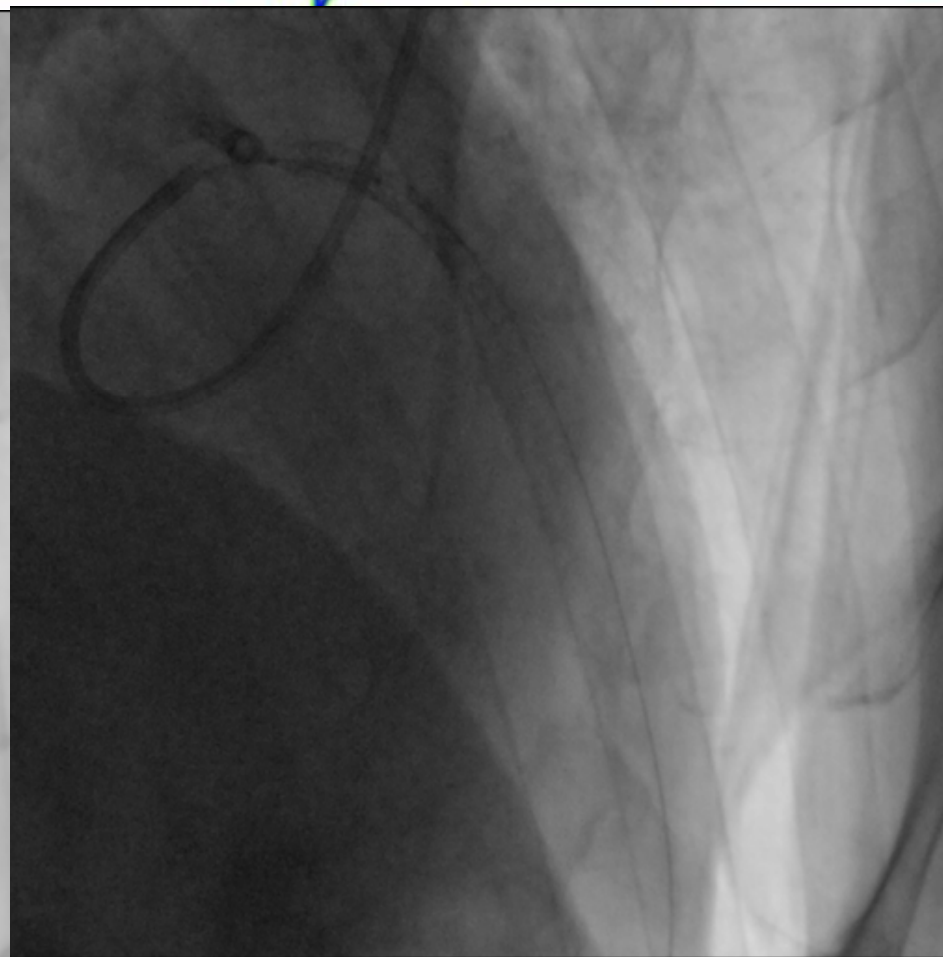




NINGBO 1st HOSPITAL



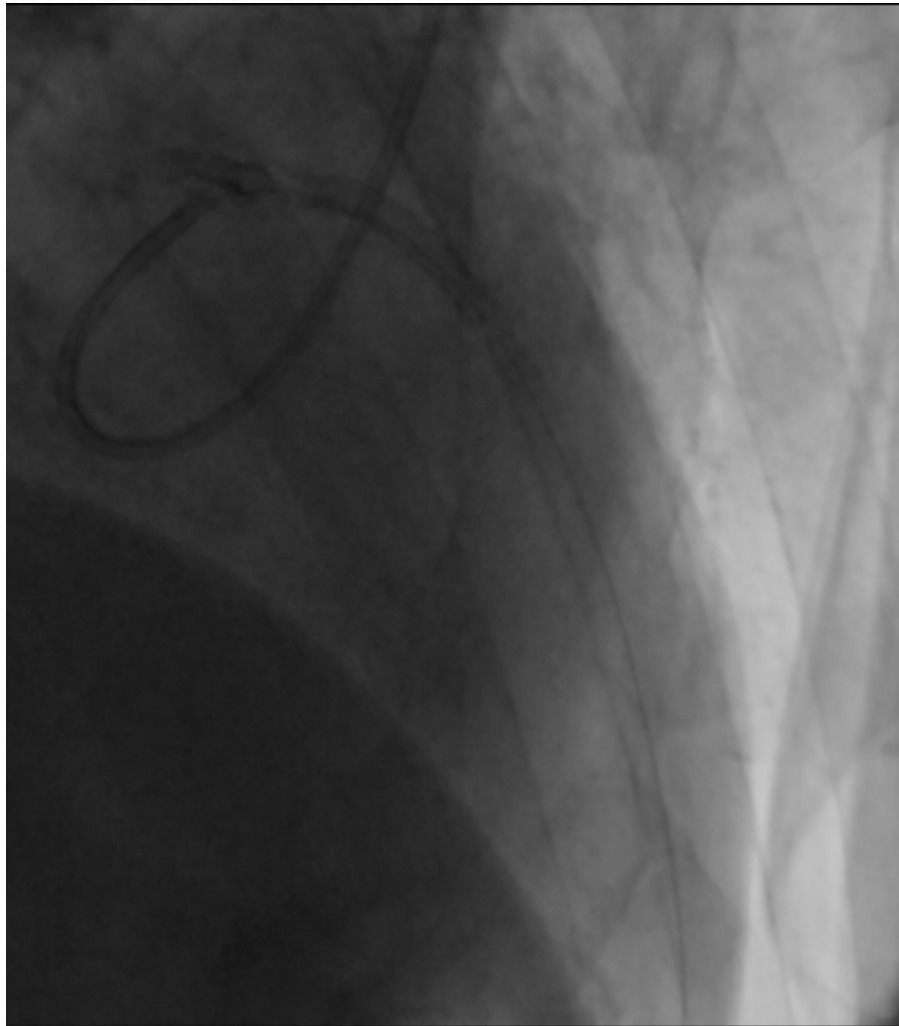
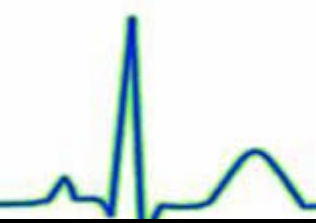
Xience V 3.5*23mm



Voyager NC 3.75*12mm



NINGBO 1st HOSPITAL



2010-11-25
14:01

